

The NZVA Elbow Dysplasia Scheme

Information for owners

Introduction

Elbow dysplasia is the name for a group of diseases that affect the elbow joint in growing dogs and all lead to premature arthritis. There are five (5) conditions of the elbow joint that are considered as "Elbow dysplasia":

1. Osteochondrosis dissecans (OCD) of the medial humeral condyle
2. Fragmented medial coronoid process of the ulna
3. Un-united anconeal process (UAP) of the ulna
4. Incongruity of the elbow joint leading to arthritis
5. Un-united medial epicondyle

Historically, it was thought that all the syndromes were manifestations of osteochondrosis, a disorder of cartilage development. It is now thought that lesions 2, 3 and 4 are related to asynchronous growth rates of the three elbow joint bones, leading to a misshapen joint. Certain forms of elbow dysplasia are more common in different breeds; OCD is seen mostly in Labradors in New Zealand and UAP is almost exclusively seen in German Shepherds or Mastiffs. Studies have shown that elbow dysplasia has a high heritability (i.e. the parent's genes strongly influence the off-spring's risk of developing the trait), although heritability estimates vary from breed to breed and for each form of the disease. Certain environmental factors such as rapid growth, high caloric feed intake and excessive exercise may also influence the severity of the disease.

Presentation

Elbow dysplasia usually shows up in three different ways:

1. Lameness or altered stance/gait in one or both forelimbs at a young age (5–12 months).
2. Mature dogs that become lame (frequently chronic) because of osteoarthritis.
3. Dogs that have radiographic signs of the disease but are free of clinical signs.

Diagnosis

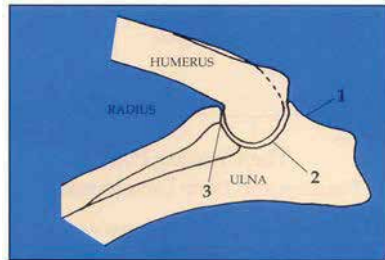
Clinically affected dogs may show episodes of lameness, and/or have an altered stance or gait. Manipulation of the elbow may reveal pain, a reduced range of motion, muscle atrophy, and swelling of the joint. A diagnosis of elbow dysplasia and identification of the type and extent of the changes can be made by radiographs (x-rays) of the joint, arthroscopy or surgical exploration.

Since radiography is non-invasive, it is the most frequently used technique. A variety of radiographic views are used. In some cases, the exact nature of the dysplasia can be identified, but in others the interpreters rely on the presence of osteoarthritic changes that would not be expected in young dogs.

In some young, affected dogs such radiographic changes may not be apparent, necessitating repeat radiographs at a later age or use of one of the other investigative techniques (recommended for lame dogs).

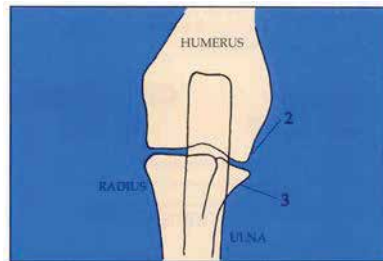
Treatment

Treatment of elbow dysplasia is aimed at minimizing the dog's discomfort and slowing the progression of osteoarthritis. A variety of medications and surgical procedures exist and the exact treatment protocol followed can be tailored to the individual dog. Therapy options selected depend on the form of dysplasia present, its severity, the degree, rate of progression, and duration of osteoarthritis, as well as the disability, pain and response shown by the dog. Adherence to a weight control programme and selection of a suitable exercise strategy are also advisable. Individual response to treatments is variable, and depends not only on the above factors, but also on the dog, its age, and use.



Flexed lateral radiograph of normal elbow

1. Anconeal process and site of early arthritis formation
2. Site of osteochondrosis of the medial humeral condyle
3. Site of fragmented medial coronoid process of ulna



Craniocaudal radiograph of normal elbow

Screening for Elbow Dysplasia

Since elbow dysplasia is highly heritable, it is prudent to identify affected dogs prior to breeding so that there is reduced risk of passing this undesirable trait onto the progeny. Screening is based on assessing two radiographic views of each elbow joint of dogs one year and over: a flexed lateral view, and a craniocaudal view. It is important that all breeding dogs of at-risk breeds are screened, since even clinically free dogs may show radiographic signs of the disease.

One of a panel of veterinarians evaluate the radiographs and identify and grade any osteoarthritic changes. Accredited dogs are those that show no radiographic signs of the disease at 12 months of age or older.

Analysis of the NZVA's database has shown a positive effect of the scheme with the incidence of elbow dysplasia dropping in all four breeds (German Shepherd, Golden Retriever, Labrador Retriever and Rottweiler) between 1992 and 2008.

How the scheme works

The NZVA Elbow Dysplasia Scheme works in much the same way as the PennHip Scheme. You will be required to fill in an online form with your dog's description, pedigree details, microchip number and Dogs New Zealand registration number (if applicable). Your veterinarian is responsible for submitting this online and paying the fee. Radiographs are scored online and the result takes one to two weeks. Each dog receives a grade for each elbow from zero (non-dysplastic) to three. If a dog has two non-dysplastic elbows it is accredited as free from elbow dysplasia.

While the individual details are confidential, the summarised breed range of scores are be integrated into New Zealand and potentially international statistical data. Results and an explanation of elbow dysplasia grades are posted on the website www.nzva.org.nz.

Selection of a new puppy

When selecting a new puppy it is wise to enquire about elbow and hip dysplasia in the family. Selecting a puppy from parents who are free of these diseases will markedly reduce the likelihood of that puppy developing problems. Certain environmental factors may influence the development of elbow dysplasia. A balanced diet fed in moderation and controlled exercise during the first year of life may help reduce the severity of the disease.

Summary

Elbow dysplasia is a genetic disease of medium to large breed dogs. With the increasing popularity of large breeds, elbow dysplasia is becoming a significant problem in New Zealand. Screening, controlled breeding and progeny testing will help control this disease.